

# Utrecht 1958: Radioactivity Alarm after Nasopharyngeal Radium Irradiation

Kees Graamans\*

## Abstract

Otitis media with effusion and other adenoid-related disorders were frequently treated by nasopharyngeal radium irradiation in the Netherlands where it was reported to be an effective therapy. Its use started in 1945 and decreased sharply in 1958, following a surge of publicity around the dramatic events in the treatment of a 5-year-old patient in Utrecht, enhancing the widespread fear of radioactivity. This case history illustrates the powerful role of the media in medical decision-making.

## Key words

nasopharyngeal irradiation, radium, otitis media with effusion, adenoid

## Introduction

Nasopharyngeal radium irradiation, also known as Crowe's radium therapy, was widely performed in the Netherlands in the 1950s. The usual indication was otitis media with effusion, at that time called 'tubal deafness', mostly in combination with other adenoid-related symptoms such as chronic rhinitis, nasal obstruction and habitual mouth breathing. The first choice in these cases was an adenoidectomy, but this was frequently ineffective. Patients with refractory symptoms after adenoidectomy used to be referred to regional centers equipped for radium irradiation of the nasopharynx. Whereas this treatment was reported to have excellent results, its application declined sharply after media coverage of a dramatic case in 1958.

## Case history

The patient was a 5-year-old girl who was living in the village of Putten in the Netherlands in 1958 (*Figure 1*). She suffered from chronic rhinitis and hearing loss, resulting from otitis media with effusion. In July




Figure 1.  
*The patient at the age of 5 years in 1958.*

1957 she had undergone adenoidectomy in a regional hospital, but the outcome was disappointing as the nasal obstruction and hearing loss did not resolve. Therefore she was referred to the ORL department of the University Hospital Utrecht, some 50 km from her home. On Wednesday morning, January 15, 1958 she arrived at the hospital accompanied by her father. The therapy was started around 11 o'clock a.m. in a separate room where the radium capsules were stored, each

---

\*Kees Graamans MD, PhD  
Professor Emeritus Otorhinolaryngology,  
Head and Neck Surgery  
Eversweg 7  
6523 LT Nijmegen  
The Netherlands  
E-mail: [k.graamans@chello.nl](mailto:k.graamans@chello.nl)

mounted on an applicator, a sort of needle, and secured in a lead container. A resident arrived and inserted the applicator in the patient's nose and set the alarm clock for 8 min 30 sec, the duration of irradiation on one side of the nose. The applicator was then removed and the procedure was repeated on the other side. When the alarm clock went off for the second time another doctor came in and removed the applicator. Afterwards the patient was sent home. Around 22 o'clock, she showed signs of nausea and started vomiting. Her father grabbed a newspaper and collected the vomit, then shoved this paper into the coal-burning heater. In the fifties and sixties most houses in the Netherlands had a coal fire in the living room and it was not unusual to burn all kinds of litter in it. Afterwards the patient returned to bed and slept well.

The next day, another patient had to be treated with radium therapy in the University Hospital Utrecht. Upon checking the equipment, it became apparent that the radium capsule that belonged on one of the applicators was missing. A major alarm was sounded and an immediate search was started. The office was thoroughly examined with Geiger counters but nothing was found. The corridors and the other rooms of the department were inspected as well. Nothing was found. It was concluded that the capsule had been left in the body of the patient. There was no telephone at her home, so the police in Putten were called to warn the family and to convince them to bring her as soon as possible to the hospital in Utrecht (Figure 2). When she arrived there early in the afternoon, she was examined with X-rays and a Geiger counter. No radium cylinder and no

radioactivity were found. The radium cylinder could not have disappeared, so it was decided to inspect the patient's home with Geiger counters. In the meantime the patient and her family had to remain at the hospital (Figure 3).



Figure 2.  
*The patient and her family arriving at the University Hospital Utrecht on Thursday, January 16, 1958.*

The next day, Friday January 17, a team of investigators arrived at the house in Putten and started their search with Geiger counters. Evidence of radiation was found in the living room, the chimney and the garden. Now it became clear that the patient's nasal secretions and vomit had reached the heater and the chimney. The garden was contaminated because the father had scattered the ashes on the snow-covered path to make the area less slippery.

The patient and her family, consisting of three sisters, one brother, her father



Figure 3.  
*The quarantine outbuilding of the University Hospital Utrecht where the family stayed during six weeks.*




Figure 4.  
*The patient and her sisters and brother leaning out of the quarantine outbuilding.*



and her mother, had to stay at the hospital (Figure 4). A major clean-up operation was initiated. All persons in the neighborhood were checked for radioactive contamination (Figure 5). The school next door was closed and the pupils were sent home, after being checked with Geiger counters (Figure 6 right).



Figure 5.  
*Shoes are examined with a Geiger counter.*



Figure 7.  
*A barbed-wired fence around the house and a warning sign: 'life danger'.*

A barbed-wire fence was erected around the house with signs saying 'life-threatening danger' (Figure 7 above). The site was placed under continuous police surveillance (Figure 8). The garden was covered with a plastic tarpaulin, firmly secured with stones (Figure 9, p.102).



Figure 6.  
*A pupil of the neighboring school is examined with a Geiger counter.*



Figure 8.  
*The house of the family is under continuous police surveillance.*






Figure 9.  
The garden is covered by a plastic tarpautin, firmly secured with stones.




Figure 11.  
*The protective gear for the cleaning team included gas masks.*



Figure 10.  
*Marine personnel with special protective clothing enter the house to start the cleaning operation.*




Figure 12.  
The chimney is dismantled.



In the military, the best expertise to deal with radioactive contaminations was in the Marine Corps, so the Marines were called upon to carry out the cleaning job. A team of Marine personnel wearing special protective clothing entered the house (*Figures 10-11 left page*). Their plan was to tear down and remove all parts that were contaminated, starting with the heater and the chimney (*Figure 12 left page*). Sections of the walls and floors were torn out and broken up into small pieces. A layer of about 20 cm was dug off the surface of the ground in the garden. The removed material and the contaminated soil were sealed in 28 concrete drums, which were then packed in wooden cases (*Figure 13*). These cases were loaded on two special trucks that had a concrete barrier between the cabin and the load in order to protect the driver from



Figure 13.  
*The concrete drums with radioactive debris are packed in wooden cases. Note the man pointing with a Geiger counter.*

radiation. On February 10 the radioactive debris was transported to the naval base in Den Helder and loaded aboard the cruiser *H.Ms. De Zeven Provinciën*. The media were told that the drums had been dumped in the Atlantic Ocean at a depth of about three km, far off the coast and far from fishing grounds. Years later the truth came out: the drums had been dumped in the North Sea only 40 km offshore at a depth of just 30 m. This was not the only scandal, however. As it turned out, there was a mismatch between the size of the concrete drums and the surrounding wooden casing such that some of the drums did not sink but kept floating on the waves. Gunners were called in to shoot holes in the casing. To this day it is unknown whether this manner

of disposal has caused any radioactive contamination of the sea water.

The house in Putten was renovated. On February 26, the patient and her family could return home after a stay of six weeks in the quarantine outbuilding at the University Hospital Utrecht. She was warmly welcomed by the inhabitants of Putten and received by the mayor (*Figure 14*). There was extensive



Figure 14.  
*The mayor of Putten welcomes the patient when she returns home after a stay of six weeks at the University Hospital Utrecht.*

press coverage of her return home. For a long time afterwards, however, she was more or less stigmatized, since some people believed that she was a source of radioactivity. Some parents did not allow their children to play with her, as they thought she might jeopardize their health.

In the beginning she frequently went to the hospital for follow-up. It is not known whether the rhinitis and otitis were cured, but she grew up in good health (*Figure 15 next page*). She married and gave birth to two healthy children; now, at 63, she is a grandmother of two (*Figure 16 next page*). Apparently the whole event has not led to any negative sequelae. The radium capsule was probably not stuck in her nasopharynx for the whole



Figure 15 & 16  
The patient at the age of 25 years and at  
the age of 63 years.

day after its insertion. It is almost certain that she had swallowed it and that most of the radiation was therefore not targeted to her nose and nasopharynx but to her intestine during most of the day. Anyhow, in the course of 58 years, no radioactivity-related disorders have been demonstrated.

#### **Nasopharyngeal radium irradiation in the Netherlands before 1958**

Doctor Samuel Crowe (1883-1955) initiated radium therapy in 1926.<sup>(1)</sup> This treatment was given to submariners and Allied Air Force personnel during World War II. At that time bomber and fighter planes could reach altitudes of 10 km and the cabins of planes in the European theatre were not pressurized. As a result the crew was exposed to unphysiological low pressures and extreme atmospheric changes. Aero-otitis was the result. This disorder was very common among aviators and a major source of their incapacity. The total number of US military personnel treated for it in World War II is 8170.<sup>(2)</sup> Nasopharyngeal radium irradiation was reported to be highly effective in the treatment of aero-otitis.

In 1945 this therapy was started in the Netherlands in children with adenoid-related disorders, mainly otitis media; the results were good, even excellent, particularly on hearing.<sup>(3)</sup> Adenoidectomy remained treat-

ment of choice for these patients, but the nasopharyngeal irradiation appeared to be very useful, particularly in refractory cases. Between 1945 and 1981 about 24,000 children in the Netherlands were treated in this way.<sup>(4)</sup> Worldwide, approximately 500,000 to 2.5 million persons underwent nasopharyngeal radium irradiation.<sup>(5)</sup> In the fifties it was rather common to treat benign disorders with radiation. Before 1958 very few authors had warned of possible adverse side effects, in particular of the induction of malignancies.<sup>(6,7)</sup> Nevertheless, nasopharyngeal irradiation was considered a highly effective and safe way to treat children for otitis media with effusion and other adenoid-related symptoms.

#### **Nasopharyngeal radium irradiation in the Netherlands after 1958**

Reports on the dangers of nasopharyngeal irradiation appeared mainly after 1958, gradually raising increasing awareness of possible long-term side effects such as the induction of malignant tumors. In these publications an increased risk of brain tumors is suggested, but never on convincing scientific grounds.<sup>(8-14)</sup>

On the other hand, some reports on follow-up examinations revealed no malignancies at all, and these authors considered nasopharyngeal irradiation to be safe.<sup>(15-17)</sup>

The failed application of nasopharyngeal radiotherapy in Utrecht in 1958 prompted widespread publicity, initially in the Netherlands, but soon extensive reports and commentary appeared in newspapers around the world. It was a time of heightened political unrest and fear of a nuclear East-West conflict. The first nuclear reactors had been put into operation, but the risks were still unclear. In 1958, words like 'radioactivity', 'fallout', 'nuclear' and 'radiation' had a threatening and alarming undertone.

The media avalanche after the events in Utrecht in 1958 marked an abrupt turning point in the application of radium therapy. Suddenly the risks of irradiation were widely discussed and both patients and doctors expressed reservations about the benefits of this therapy. Immediately after February 1958, the number of institutions that performed this treatment in the Netherlands decreased sharply (*Figure 17*). In the late sixties the decline was accelerated by the advent of tympanotomy tubes. Eventually, the nasopharyngeal irradiation was abandoned; the last time it was applied in the Netherlands was 1981.

## Conclusion

There is no doubt that the publicity around just one instance of failure of a therapy has greatly influenced the management of a common disorder. The Utrecht incident of 1958 brought about an immediate and radical change in the management of otitis media with effusion in children. It is amazing to see how much impact the public media -radio, television and newspapers- can have on medical decision-making. Whereas scientific research is meant to improve medical practice, its influence is limited. The decline in the application of nasopharyngeal radium therapy was not brought about by ongoing scientific investigations and increasing insight. The lesson of history is that accidents and scandals are much more powerful forces for change than scientific evaluations.

## Acknowledgement

Mrs. Joke Kappers-Haanschoten was an invaluable source of information providing many details and supplying a variety of newspaper articles from 1958.

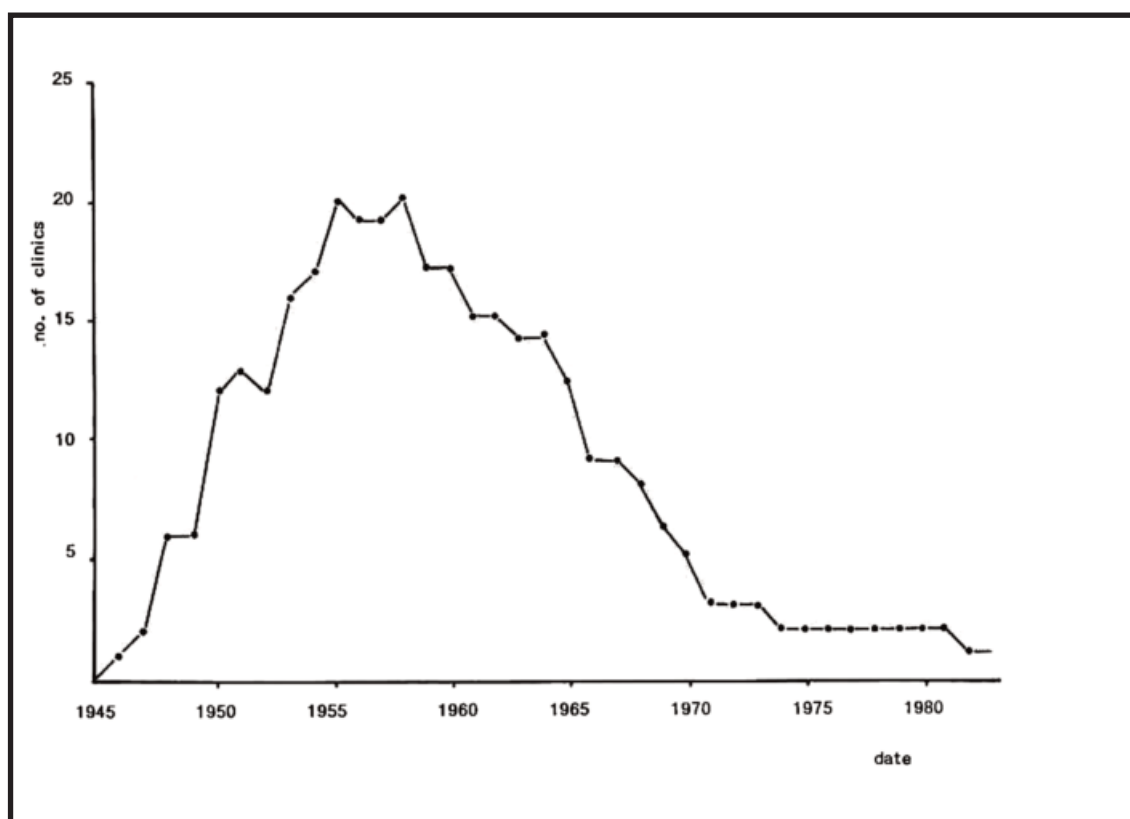


Figure 17.  
Numbers of institutions offering nasopharyngeal radium irradiation in The Netherlands between 1945 and 1981. A sharp decline starts after 1958.<sup>(4)</sup>



## References

1. Crowe SJ, Baylor JW. The prevention of deafness. *J Med Am Med Assoc* 1939;112:585-590.
2. Warlick SR. Military use of nasopharyngeal irradiation with radium during World War II. *Otolaryngol Head Neck Surg* 1996;115:391-394.
3. Dishoeck HA. Bestraling van de nasopharynx met radium. *Ned Tijdschr Geneeskde* 1950;94:224-227.
4. Verduijn PG. Late health effects of radiation for eustachian tube dysfunction. A non-concurrent prospective study. Thesis, Erasmus University Rotterdam, 1988, p.134.
5. Mellinger-Birdsong AK. Estimates of numbers of civilians treated with nasopharyngeal radium irradiation in the United States. *Otolaryngol Head Neck Surg* 1996;115:429-432.
6. Robbins LL, Schulz MD. Potential hazards from radiation treatment of hypertrophied lymphoid tissue in the nasopharynx. *Laryngoscope* 1949;59:147-155.
7. Loch WE, Fischer ND. Nasopharyngeal radium treatment: a follow-up study of 263 patients. *Ann Otol Rhinol Laryngol* 1952;61:198-205.
8. Hazen RW, Pifer JW, Toyooka ET, Livingston J, Hempelmann LH. Neoplasms following irradiation of the head. *Cancer Res* 1966;26:305-311.
9. Sandler DP, Comstock GW, Maranoski GM. Neoplasms following childhood irradiation of the nasopharynx. *J Natl Cancer Inst* 1982;68:3-8.
10. Verduijn PG, Hayes RB, Looman C, Habema JD, Van der Maas PJ. Mortality after nasopharyngeal radium irradiation for Eustachian tube dysfunction. *Ann Otol Rhinol Laryngol* 1989;98:839-844.
11. Sandler DP. Nasopharyngeal radium irradiation: the Washington County, Maryland, study. *Otolaryngol Head Neck Surg* 1996;115:409-414.
12. Verduijn PG. Late health effects of radiation for Eustachian tube dysfunction: previous results and ongoing study in The Netherlands. *Otolaryngol Head Neck Surg* 1996;115:417-421.
13. Yeh H, Matanoski GM, Wang NY, Sandler DP, Comstock GW. Cancer incidence after childhood nasopharyngeal radium irradiation: a follow-up study in Washington County, Maryland. *Am J Epidemiol* 2001;153:749-756.
14. Ronckers CM, Van Leeuwen FE, Hayes RB, Verduijn PG, Stovall M, Land CE. Cancer incidence after nasopharyngeal radium irradiation. *Epidemiology* 2002;13:552-560.
15. Loeb WJ. Radiation therapy of the nasopharynx: a 30 year view. *Laryngoscope* 1979;89:16-21.
16. Pratt LW. Nasopharyngeal irradiation treatment of hyperplastic adenoids. *Otolaryngol Head Neck Surg* 1981;89:47-53.
17. Proctor DF. Historic development and medical use of nasopharyngeal radium irradiation treatments. *Otolaryngol Head Neck Surg* 1996;115:388-390.